

Elbow Arthritis and Total Elbow Replacement

Lee A. Kaback, MD, Andrew Green, MD, and Theodore A. Blaine, MD

ARTHRITIC INVOLVEMENT OF THE ELBOW IS RELATIVELY UNCOMMON.

However, because of the critical role that the elbow plays in hand and upper extremity function arthritis can be functionally disabling. The most common etiologies of elbow arthritis are primary degenerative arthritis (osteoarthritis), rheumatoid and inflammatory arthritis, and post traumatic arthritis. Other less common conditions include hemophilic arthropathy, synovial chondromatosis, and post infectious arthropathy. Treatment is dependent on the extent of pathologic involvement and predicated on relieving pain and restoring function.

RELEVANT ANATOMY

The elbow joint is comprised of complex articular anatomy and associated ligamentous and musculotendinous structures and the elbow is biomechanically critical to upper extremity function.¹ The elbow is considered to be a trochoginglymoid joint because it has both hinge and rotational motion. The articular geometry is very constrained and critically important to joint stability. In addition the medial and lateral ligament complexes play an important role in elbow stability and function.

Even minor trauma or transient disease involvement can result in prolonged, limited, if not permanent, painful motion. Although the elbow is not commonly considered a weight-bearing joint, static loading forces can equal three times body weight, which increase to 6 times with dynamic loading.^{1,2}

PRIMARY DEGENERATIVE ARTHRITIS

Primary degenerative arthritis (osteoarthritis (OA)) of the elbow is a rare condition, affecting fewer than two percent of the population.³ It is most commonly seen in men at a ratio of about four to one²⁻⁵ and typically affects individuals who are involved in heavy use such as manual labor and weight lifting.^{4,5} The dominant extremity is involved in 80 to 90 percent of patients, and bilateral involvement is present in about 25 to 60 percent. Elbow OA is characterized by pain, limited motion, mechanical symptoms, and weakness. Loss of terminal elbow extension and impingement-type pain at terminal extension and flexion are common in the earlier stages of the disease process. Classically, a patient will report pain when carrying heavy objects at the side of the body with the elbow in extension. In the later stages, the elbow progresses to a greater degree of motion loss and pain in the mid-arc of motion. Unlike other joints, osteoarthritis of the elbow is characterized by relative preservation of the articular cartilage joint surface with maintenance of joint space, but with hypertrophic osteophyte formation and capsular contracture.

The extent of the radiographic findings usually correlates with the patient's symptoms. Osteophyte formation on the tip of the olecranon and in the olecranon fossa leads to pain and limitation of elbow extension, while osteophytes on the coronoid and in the coronoid and radial fossae leads to pain and limitation of elbow flexion. (Figure 1) Secondary changes include osteophytes at the margin of the radial head and loose bodies. Occasionally the radiohumeral joint is selectively involved.⁶ Because of excessive osteophyte formation in the region of the cubital tunnel ulnar nerve irritation is observed in at least ten percent of these patients. CT

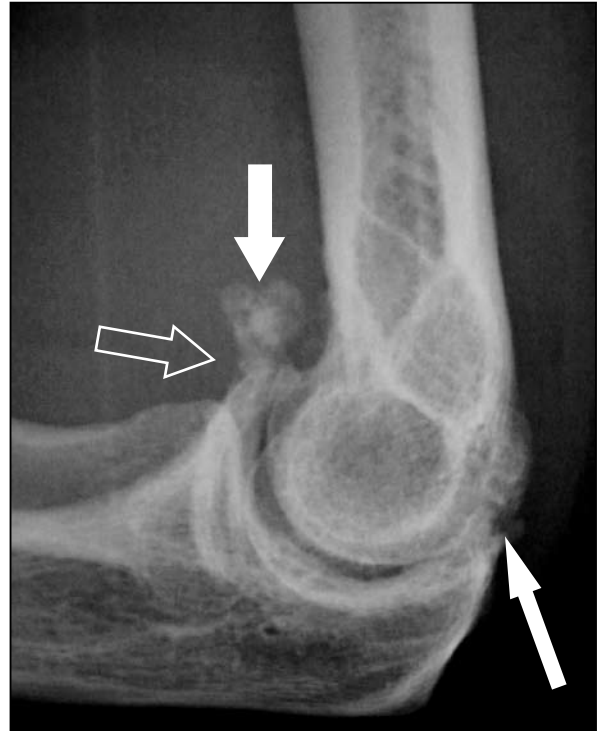

Figure 1. Lateral radiograph in a patient with elbow osteoarthritis. Osteophytes are present both on the coronoid (open arrow) and olecranon (narrow arrow) limiting both flexion and extension. There is a large loose body in the anterior joint space (filled arrow).

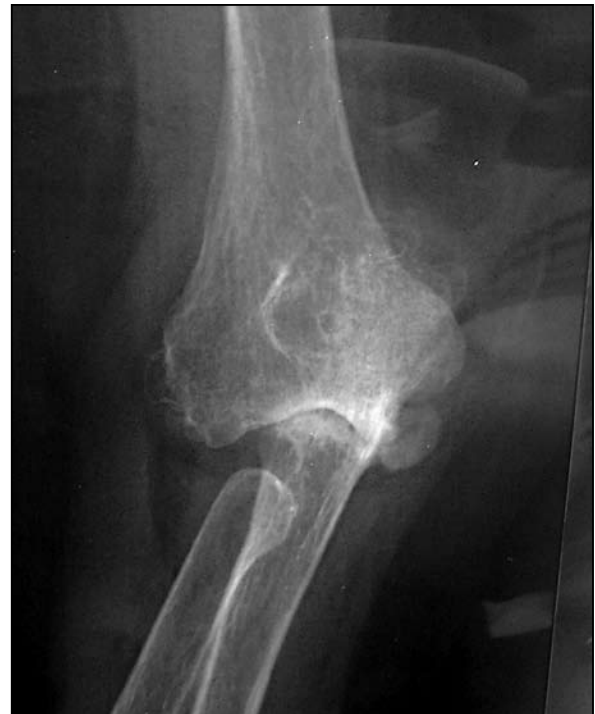

Figure 2. Anteroposterior radiograph of the right elbow in a patient with Grade IV rheumatoid arthritis.

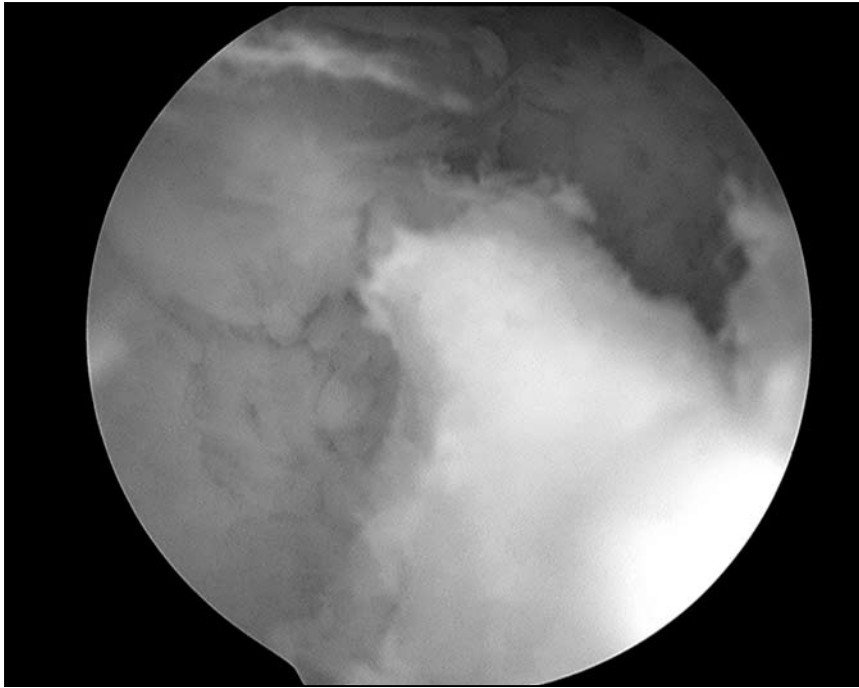


Figure 3. Intraoperative arthroscopy photo in a patient with osteoarthritis showing a large coronoid osteophyte impinging in the anterior elbow joint.




Figure 4. Intraoperative photo showing multiple loose bodies which have been removed from a patient with elbow OA.

scans are often helpful in these patients for delineating the pathology and location of osteophytes and loose bodies.

RHEUMATOID ARTHRITIS

Rheumatoid arthritis is a systemic inflammatory disease that is characterized by polyarticular involvement. Rheumatoid arthritis, in contrast to primary

degenerative arthritis of the elbow, is characterized by more severe articular surface involvement and joint destruction. Between 20 and 50 percent of patients with rheumatoid arthritis demonstrate elbow involvement, usually within five years of disease onset. Isolated presentation of RA of the elbow occurs in only about five percent of patients.⁷

Rheumatoid arthritis of the elbow is staged or graded according to the extent of pathologic involvement and reflects soft tissue, joint surface, and bony involvement. A radiographic and clinical system for the classification of rheumatoid arthritis was developed by the Mayo Clinic. Grade I signifies normal radiographic findings except for osteopenia with mild synovitis, Grade II: loss of joint space, Grade III: loss of joint space and joint architecture, Grade IV: extensive articular damage with loss of subchondral bone and subluxation or ankylosis of the joint.⁸ (Figure 2) Unlike OA, advanced imaging modalities including computed tomography or magnetic resonance imaging scans are usually not needed to diagnose or treat rheumatoid arthritis. However, in early cases of rheumatoid involvement MRI is useful to determine the extent of synovitis which can be treated with synovectomy.

The earliest presentation is usually the result of synovitis and is characterized by pain, mild limitation of motion, and joint effusion and swelling. Progressive disease advancement results in loss of articular cartilage, peri-articular soft tissue destruction, and bony destruction, eventually leading to complete joint destruction with bone loss and instability. The recent use of disease modifying pharmaceuticals has substantially reduced the incidence of advanced rheumatoid involvement of the elbow. The extent of involvement of the shoulder and wrist should be considered when determining the treatment of patients with rheumatoid arthritis of the elbow.

POST TRAUMATIC ARTHRITIS

Post-traumatic arthritis of the elbow is most commonly a sequela of comminuted displaced intra-articular fractures of the distal humerus. These fractures are extremely challenging to treat. For this reason, elbow replacement has been advocated as an alternative to open reduction and internal fixation in elderly low demand individuals.⁹ Overall, post-traumatic elbow arthritis is less common than primary degenerative and rheumatoid arthritis. These patients often have limited motion secondary to soft tissue contracture and heterotopic ossification. However, the typical patient is younger with greater physical and functional demands, as well as expectations. Conse-

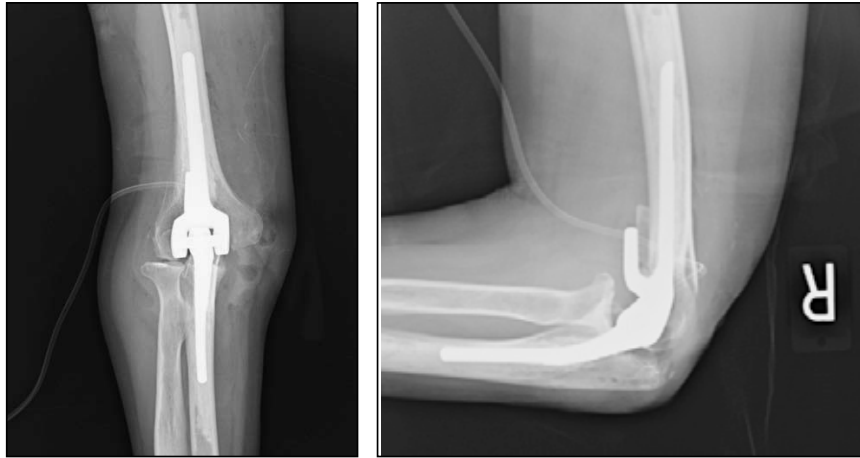

Figure 5A (left) and B (right). Postoperative radiographs of the right elbow in a patient after total elbow arthroplasty for endstage rheumatoid arthritis.

quently, the risk of failure of total elbow arthroplasty is higher and the survivorship lower when compared to patients with rheumatoid arthritis, and alternative treatments should be considered prior to considering joint replacement.

TREATMENT

In the early stages of all etiologies of elbow arthritis most patients can be treated with nonoperative modalities. These include oral non-steroidal anti-inflammatory medications and activity modification. Some patients may benefit from intra-articular injections of corticosteroids or hyaluronans.¹⁰ Physical therapy should emphasize pain control measures (avoidance of activities that place stress on the elbow, regular periods of rest, and application of heat or cold), stretching and range of motion exercises to encourage maintenance of mobility, and careful gentle strengthening exercises. Hinged elbow braces may be used to provide comfort during flexion and extension while limiting painful varus and valgus stresses. Turnbuckle braces or static progressive splints may be used to restore loss of motion.

If these non-operative modalities fail to relieve the patient's symptoms, operative treatment options including arthroscopic, open non-arthroplasty, and elbow arthroplasty can be considered. Each has specific indications and technical considerations that relate to the underlying diagnosis.

In past years open non-arthroplasty surgery had a substantial role in the treatment of primary degenerative arthritis and rheumatoid arthritis of the elbow. Open debridement and removal of hypertrophic

spurring with capsular release was often performed to treat primary degenerative osteoarthritis. The Outerbridge-Kashiwagi procedure prevents impingement of osteophytes by making a hole in the distal humerus. A number of studies reported high rates of satisfactory outcomes with pain relief and functional improvement.¹¹⁻¹³ Similarly, open synovectomy with or without radial head excision was a mainstay in the management of rheumatoid arthritis. An even greater number of studies reported successful outcomes with pain relief and improved range of motion even in patients with moderately severe rheumatoid arthritis.¹⁴⁻¹⁵

More recently, arthroscopic surgery has assumed a prominent role in the management of elbow arthritis. Arthroscopic surgery is minimally invasive and facilitates extensive intra-articular surgery while avoiding the morbidity of the equivalent open procedures. Arthroscopic debridement of the elbow for primary osteoarthritis or grade I or II rheumatoid arthritis has demonstrated successful outcomes for pain relief, restoration of motion, and functional improvement.¹⁶⁻¹⁹ (Figure 3) This procedure allows for removal of loose bodies, synovectomy, debridement and capsular release, and removal of prominent osteophytes. (Figure 4) Elbow arthroscopy however is technically difficult and should only be performed by experienced surgeons to avoid injury to key neurovascular structures. Where arthroscopy is not possible, open debridement is a safe and effective debridement procedure to remove extensive osteophytes and release capsular contractures.²⁰ Concomitant ulnar nerve decompression or transposition

is performed if there is associated ulnar neuropathy or elbow flexion limited to 90 degrees or less.

In rare cases of open debridement and where a prosthesis is contraindicated, non-prosthetic arthroplasty with an interposition material (cutis, tendon graft, etc.) can be performed to resurface the joint. The efficacy of this procedure is debated and there is a significant risk of complications.²¹

Total elbow arthroplasty (TEA) is a reliable procedure for the treatment of elbow arthritis when other interventions have failed. Pain is the most common indication for total elbow arthroplasty (TEA); most patients requiring TEA will have pain throughout the arc of motion. Although there are many total elbow replacement designs available, they are generally classified as linked (hinged) semi-constrained or unlinked. The former are required in patients with poor quality elbow ligaments and periarticular soft tissues and are commonly used in patients with advanced rheumatoid arthritis. The latter are unconstrained, require intact ligaments, and are typically used in more mildly involved rheumatoid elbows, primary degenerative arthritis, and some post-traumatic arthritis cases. (Figures 5A and B) Until recently, rheumatoid arthritis was by far the most common indication for total elbow arthroplasty.

Total elbow arthroplasty is ideally suited for lower demand patients. This describes the typical patient with rheumatoid arthritis of the elbow. Excessive use, as might be expected of younger active patients, is associated with earlier implant loosening and failure. Patients considering TEA must be willing to accept post-operative restrictions, including: no lifting more than 10 pounds at any event, and no repetitive lifting of more than two pounds.²² Rehabilitation following TEA is focused initially on soft tissue healing. Depending on the surgical approach, triceps protection including avoiding active extension against resistance is important in the early post-operative period. Most patients are able to regain an excellent range of elbow motion after surgery, and most patients are able to perform activities of daily living within four to six weeks.

Survivorship analysis studies of total elbow arthroplasty for the treatment of rheumatoid arthritis demonstrate 92.4 percent survival of implants at ten years.²³

In general, the survivorship is comparable to total hip replacement, and outcome studies demonstrate that the success rate of total elbow arthroplasty for rheumatoid arthritis approaches that following total knee arthroplasty.^{24,25} In contrast, the survivorship of total elbow arthroplasty in patients with primary degenerative and post-traumatic arthritis is substantially shorter and careful consideration should be given when considering treatment of these patients.²⁶ These patients are typically younger, more active and have solitary joint involvement with greater expectations for functional use.

As with all joint arthroplasty surgery, total elbow arthroplasty is associated with complications. Complications can be generally grouped as either intra or peri-operative (directly related to the surgical procedure) or late. The most common intra- or peri-operative complications are ulnar neuropathy, triceps insufficiency and weakness, and infection. The most common late complications or problems are aseptic loosening, implant failure, and peri-prosthetic fracture. Infection and periprosthetic fractures are especially problematic and often necessitate multiple surgical procedures.²⁷⁻³⁰ Fortunately, these complications are not common.

SUMMARY

Elbow arthritis is a relatively uncommon condition that can be successfully managed with non-operative and operative methods. The extent of pathologic involvement and severity of pain and dysfunction are the most important factors in selecting treatment. Arthroscopic, open, and arthroplasty surgery options provide successful outcomes in most cases.

REFERENCES:

- Morrey BF, Askew LJ, Chao EY. A biomechanical study of normal functional elbow motion. *J Bone Joint Surgery Am.* 1981;63-A(6):872-7.
- Morrey BF. Applied anatomy and biomechanics of the elbow joint. Instructional Course Lectures, American Academy of Orthopaedic Surgeons, Rosemont, Il 1986;35:59-68.
- Stanley D. Prevalence and Etiology of Symptomatic Elbow Osteoarthritis. *J Shoulder Elbow Surg.* 1994;3:386-9.
- Morrey B. Primary arthritis of the elbow treated by ulno-humeral arthroplasty. *J Bone Joint Surgery Br.* 1992;74B:409.
- Doherty M. Primary osteoarthritis of the elbow. *Ann Rheum.* 1989;48:473.

- Delal S. Radiographic changes at the elbow in primary osteoarthritis: a comparison with normal aging of the elbow joint. *J Shoulder Elbow Surg.* 2007;16:358.
- Inglis A. Septic and non-traumatic conditions of the elbow: Rheumatoid arthritis. *The Elbow and its Disorders*, ed 2. 1993:751-66.
- Morrey BF, Adams RA. Semiconstrained arthroplasty for the treatment of rheumatoid arthritis of the elbow. *J Bone Joint Surgery Am.* 1992;74-A(4):479-90.
- McKee MD, Veillette CJ, Hall JA, et al. A multicenter, prospective, randomized, controlled trial of open reduction—internal fixation versus total elbow arthroplasty for displaced intra-articular distal humeral fractures in elderly patients. *J Shoulder Elbow Surg.* 2009;18(1):3-12.
- van Brakel RW. Intra-articular injection of hyaluronic acid is not effective for the treatment of post-traumatic osteoarthritis of the elbow. *Arthroscopy.* 2006;22:1199-203.
- Minami N. Outerbridge-Kashiwagi's Method for arthroplasty of osteoarthritis of the elbow. 44 Elbows followed for 8-16 years. *J Orthop Sci.* 1996;1:11.
- Morrey BF. Primary degenerative arthritis of the elbow. Treatment by ulnohumeral arthroplasty. *J Bone Joint Surgery Am.* 1992;74-A(3):409-13.
- Tashjian RZ, Wolf J, Ritter M, Weiss A, Green A. Functional outcomes and general health status following ulnohumeral arthroplasty for primary degenerative arthritis of elbow. *J Bone Joint Surgery Am.* 2006;15: 357-66.
- Gendi NST, Axon JMC, Carr AJ, et al. Synovectomy of the elbow and radial head excision in rheumatoid arthritis. Predictive factors and long-term outcome. *J Bone Joint Surgery Br.* 1997;79B:918-23.
- Mäenpää HM, Kuusela PP, Kaarela K, et al. Reoperation rate after elbow synovectomy in rheumatoid arthritis. *J Bone Joint Surgery Am.* 2003;12:480-3.
- Morrey BF. Arthroscopy of the elbow. Instructional Course Lectures, American Academy of Orthopaedic Surgeons, Rosemont, Il, 1986:35:102-107.
- O'Driscoll SW, Morrey BF. Arthroscopy of the elbow. Diagnostic and therapeutic benefits and hazards. *J Bone Joint Surgery Am.* 1992;74-A(1):84-94.
- Lee BP, Morrey BF. Arthroscopic synovectomy of the elbow for rheumatoid arthritis. A prospective study. *J Bone Joint Surgery Am.* 1997;79-A(5):770-2.
- Horiuchi K. Arthroscopic synovectomy of the elbow in rheumatoid arthritis. *J Bone Joint Surgery Am.* 2002;84-A:342-7.
- Morrey BF. Nonreplacement reconstruction of the elbow joint. Instructional Course Lectures, American Academy of Orthopaedic Surgeons, Rosemont, Il, 51:63-67, 2002.
- Cheng SL, Morrey BF. Treatment of the mobile, painful arthritic elbow by distraction interposition arthroplasty. *J Bone Joint Surgery Br.* 2000 Mar;82-B(2):233-8.
- Morrey BF, Askew LJ, An KN. Strength function after elbow arthroplasty. *Clinical Orthop Related Research.* 1988;234:43-50.
- Gill DR, Morrey BF. The Coonrad-Morrey total elbow arthroplasty in patients who have rheumatoid arthritis. A ten to fifteen-year follow-up study. *J Bone Joint Surgery Am.* 1998;80-A(9):1327-35.
- Little CP. Total elbow arthroplasty: A systematic review of the literature in the English language. *J Bone Joint Surgery Am.* 2005;87-A:437-44.
- van der Lugt JC, Rozing PM. Systematic review of primary total elbow prostheses used for the rheumatoid elbow. *Clinical Rheumatology.* 2004;23(4):291-8.
- Morrey BF, Adams RA, Bryan RS. Total replacement for post-traumatic arthritis of the elbow. *J Bone Joint Surgery Am.* 1991;73-A(4):607-12.
- Voloshin I, Schippert DW, Kakar S, Kaye EK, Morrey BF. Complications of total elbow replacement: A systematic review. *J Shoulder Elbow Surg.* 2011;20(1):158-68.
- Morrey BF, Bryan RS. Complications of total elbow arthroplasty. *Clinical Orthop Related Research.* 1982;170:204-12.
- Trancik T. Capitellectomy total elbow arthroplasty. 2 to 8 years experience. *Clinical Orthop Related Research.* 1987;223:175.
- Morrey BF, Bryan RS. Infection after total elbow arthroplasty. *J Bone Joint Surgery Am.* 1983;65-A(3):330-8.

Lee A. Kaback, MD, currently works in private practice in Albany, NY, specializing in shoulder and elbow reconstruction.

Andrew Green, MD, is an Associate Professor of Orthopedic Surgery and Chief of Division of Shoulder and Elbow Surgery at the Warren Alpert Medical School of Brown University, and Practices at University Orthopedics, Inc.

Theodore A. Blaine, MD, is an Associate Professor at the Yale University School of Medicine, and Chief of Shoulder and Elbow Surgery at Yale Orthopaedics and Rehabilitation.

Disclosure of Financial Interests

Lee A. Kaback, MD, and Andrew Green, MD, have no financial interests to disclose.

Theodore Blaine, MD, is a consultant and on the speakers' bureau for Zimmer Corp, and receives grant research support from Tomier Corp.

CORRESPONDENCE

Theodore A. Blaine, MD
Yale University Department of
Orthopaedics and Rehabilitation
Yale University School of Medicine
phone: 203-737-2348
e-mail: theodore.blaine@yale.edu

Andrew Green, MD
University Orthopedics, Inc
2 Dudley Street, Suite 200
Providence, RI 02905
e-mail: agreen@universityorthopedics.com